

Extra-stent vascular remodeling in in-stent restenosis after $^{188}\text{Re-MAG}_3$ radiation therapy

Myeong-Ki Hong^a, Seong-Wook Park^a, Dae-Hyuk Moon^b, Seung-Jun Oh^b, Cheol Whan Lee^a, Young-Hak Kim^a, Jun-Hong Kim^a, Yuanchun Zhang^c, Jong-Min Song^a, Duk-Hyun Kang^a, Jae-Kwan Song^a, Jae-Joong Kim^a, Seung-Jung Park^{a,*}

^aDepartment of Medicine, University of Ulsan College of Medicine, Cardiac Center, Asan Medical Center, 388-1 Poongnap-dong, Songpa-gu, Seoul 138-736, South Korea

^bDepartment of Nuclear Medicine, University of Ulsan College of Medicine, Asan Medical Center, 388-1 Poongnap-dong, Songpa-gu, Seoul 138-736, South Korea

^cDepartment of Cardiology, the First Affiliated Hospital, College of Medicine, Shantou University, Guangdong, China

Received 26 June 2002; received in revised form 9 January 2003; accepted 12 January 2003

Abstract

Background: The effect of β -radiation on extra-stent vascular remodeling in patients with in-stent restenosis has not been studied. The correlation between the extent of extra-stent plaque proliferation and that of intimal hyperplasia (IH) in in-stent restenosis in patients who received β -radiation therapy as well as conventional therapy has also not been studied. **Methods:** We evaluated the extra-stent remodeling in diffuse in-stent restenosis between a β -radiation therapy patient group ($^{188}\text{Re-MAG}_3$, $n=50$) and a control group ($n=9$) by applying serial intravascular ultrasound (IVUS) analysis. Matching (post-intervention and follow-up) images were acquired at the follow-up lesion site and were available in 44 of 50 patients who received radiation therapy and in seven of nine control patients. **Results:** There was a significant increase of the external elastic membrane (EEM) area in both groups: $16.4 \pm 3.3 \text{ mm}^2$ post-intervention to $17.1 \pm 3.3 \text{ mm}^2$ at follow-up, $P=0.001$ in the radiation therapy group, and $16.8 \pm 4.0 \text{ mm}^2$ post-intervention to $17.4 \pm 4.1 \text{ mm}^2$ at follow-up, $P=0.008$ in the control group. There were no statistically significant differences of the Δ EEM area between the two groups: $0.7 \pm 0.4 \text{ mm}^2$ in the radiation therapy group vs. $0.6 \pm 0.4 \text{ mm}^2$ in the control group, $P=0.389$. The Δ IH area correlated with the Δ EEM area in the control group ($r=0.826$, $P=0.022$), but not in the radiation therapy group ($r=0.016$, $P=0.919$). **Conclusions:** The findings of this IVUS study were that positive remodeling (increased EEM area) occurred equally in both control and irradiated patients with in-stent restenosis. The extent of remodeling was directly in proportion to IH in the control group, but no such relationship existed in the irradiated patient group.

© 2003 Elsevier Ireland Ltd. All rights reserved.

Keywords: Restenosis; Radiation; Intravascular ultrasound

1. Introduction

Intravascular ultrasound (IVUS) allows detailed, high-quality, cross-sectional imaging of the coronary artery morphology (intima, media and adventitia) in vivo. The changes that occur in the atherosclerotic disease process, during intervention including stenting and radiation therapy, and in follow-up can be studied in vivo in a manner previously

not possible using other imaging modalities [1]. In de novo lesions, serial IVUS studies have demonstrated that the late lumen loss after stenting is almost completely the result of neointimal hyperplasia within the stent [2,3]. There is a chronic increase in plaque mass both outside as well as inside the stent. The neointimal proliferation within the stent correlates directly with the plaque mass growth outside the stent [1].

In in-stent restenosis lesions, the diffuse pattern of in-stent restenosis has been difficult to treat because of its high recurrence rate despite various kinds of treatment modalities [4–6]. Recently, several studies of intracoronary radiation

* Corresponding author. Tel.: +82-2-3010-4818; fax: +82-2-475-6898.
E-mail address: sjpark@amc.seoul.kr (S.-J. Park).

therapy in patients with in-stent restenosis demonstrated a reduction of binary angiographic restenosis and target lesion revascularization compared with a control group [7,8].

However, a number of unusual findings have been reported after radiation therapy, including aneurysm formation, black holes (echolucent neointimal tissue) and late stent malapposition, which is a separation of the stent struts from the intimal surface of the arterial wall that was not present after implantation [9]. Data on β -radiation therapy of the nonstented lesion has shown that there was significant positive remodeling (an increase of external elastic membrane (EEM) area) [10]. The combination of positive remodeling and inhibition of intimal hyperplasia (IH) appears to lead to late stent malapposition in stented lesion [9]. Therefore, remodeling pattern or change of EEM area after radiation therapy might determine the occurrence of such kinds of clinical events. In patients with in-stent restenosis, however, the effect of β -radiation on extra-stent vascular remodeling has not been studied. The correlation between the extent of extra-stent plaque proliferation and IH in in-stent restenotic lesions treated with β -radiation therapy as well as conventional therapy has also not been studied. Therefore, the objective of the current study was to use serial (post-intervention and follow-up) IVUS to evaluate extra-stent vascular remodeling in in-stent restenosis lesions after β -radiation therapy compared with a control.

2. Materials and methods

2.1. Study populations

β -Radiation therapy with a $^{188}\text{Re-MAG}_3$ -filled balloon following rotational atherectomy for diffuse in-stent restenosis (lesion length > 10 mm, diameter stenosis >50%) was prospectively performed in 50 consecutive patients [11,12]. Inclusion and exclusion criteria have been previously described in detail [11,12]. Our Institutional Review Board approved this study. Nine patients who did not agree with the radiation therapy, and who therefore underwent rotational atherectomy and balloon angioplasty for diffuse in-stent restenosis during the same study period, were selected as the control group. The baseline clinical characteristics and procedural results between the patients who had received radiation therapy and the control patients were not statistically significantly different [11].

2.2. Radiation delivery system, dosimetry, and procedure

The method of radiation therapy has been previously described in detail [11,12]. The radiation system was a $^{188}\text{Re-MAG}_3$ -filled angioplasty balloon. Liquid ^{188}Re is a high-energy β -emitter that is available daily from the $^{188}\text{W}/^{188}\text{Re}$ generator (Oak Ridge National Laboratory, Oak Ridge, TN, USA). From the dosimetry data, we

calculated irradiation time to deliver 15 Gy at 1.0 mm deep into the vessel wall from the balloon/artery interface.

2.3. IVUS imaging protocol

Post-intervention and follow-up IVUS studies were performed in identical fashion. Intracoronary 0.2 mg nitroglycerin was administered. The ultrasound catheter was advanced ~ 10 mm beyond the lesion site, and an imaging run was performed from beyond the lesion site to the aorto-ostial junction. We performed the studies using a commercially available system (Boston Scientific Corporation/Cardiovascular Imaging System, San Jose, CA, USA) which uses a 30 MHz single-element beveled transducer mounted on the end of a flexible shaft and rotated at 1800 rev./min within a 3.2 F short monorail imaging sheath. With this system, the transducer was withdrawn automatically at 0.5 mm/s to perform the imaging sequence. Ultrasound studies were recorded on 1/2-in high-resolution s-VHS tape for off-line analysis. The post-intervention IVUS imaging run was the final step in the intervention procedure. A follow-up IVUS imaging run was performed before any subsequent intervention.

2.4. Quantitative IVUS measurements

Validation of the cross-sectional area (CSA) measurements of the lumen and plaque+media by IVUS have been previously reported [13]. At each IVUS image slice, the stent, EEM, and lumen CSA were measured with a commercially available program for computerized planimetry. Serial IVUS comparisons between post-intervention and the 6-month follow-up were available in 44 of 50 patients who underwent radiation therapy and in seven of nine control patients. The remaining patients refused to undergo a 6-month follow-up angiogram. Angiographic restenosis occurred in five (11.3%) of 44 patients who received radiation therapy and in three (42.9%) of seven control patients. On playback of the post-intervention and follow-up IVUS studies, the matching (post-intervention and follow-up) IVUS image slices were acquired at the follow-up lesion site. In practice, the follow-up target slice was first identified and then the distance from this target slice to the closest identifiable axial landmark was measured (using seconds or frames of videotape). Finally, this distance was used to identify the corresponding slices on the post-intervention IVUS studies. Vascular and perivascular markings were also used to confirm the image slice identification. If necessary, the analysis was done side by side, and the imaging runs were studied frame by frame to ensure that the same matching image slices were measured.

We then made the following calculations for all lesions; (1) IH CSA (mm^2)=(stent CSA – lumen CSA); (2) Δ stent CSA (mm^2)=(follow-up – post-intervention) stent CSA; (3) Δ lumen CSA (mm^2)=(follow-up – post-intervention) lu-

Table 1
Intravascular ultrasound data

	Radiation	Control	P
No. of lesions	44	7	
Post-intervention			
EEM CSA (mm ²)	16.4 ± 3.3	16.8 ± 4.0	0.803
Stent CSA (mm ²)	8.9 ± 2.3	9.3 ± 2.7	0.700
Lumen CSA (mm ²)	5.6 ± 1.7	6.7 ± 2.7	0.249
IH CSA (mm ²)	3.3 ± 1.3	2.7 ± 1.3	0.244
Follow-up			
EEM CSA (mm ²)	17.1 ± 3.3	17.4 ± 4.1	0.864
Stent CSA (mm ²)	8.9 ± 2.3	9.3 ± 2.7	0.707
Lumen CSA (mm ²)	5.0 ± 1.8	3.7 ± 1.8	0.191
IH CSA (mm ²)	3.9 ± 2.1	5.6 ± 1.9	0.063
Δ			
Δ EEM CSA (mm ²)	0.7 ± 0.4	0.6 ± 0.4	0.389
Δ Stent CSA (mm ²)	-0.0 ± 0.1	-0.0 ± 0.0	0.418
Δ Lumen CSA (mm ²)	-0.6 ± 1.4	-2.9 ± 2.1	0.025
Δ IH CSA (mm ²)	0.6 ± 1.4	2.9 ± 2.1	0.026

Δ, (follow-up) – (post-intervention); CSA, cross-sectional area; EEM, external elastic membrane; IH, intimal hyperplasia.

men CSA; (4) Δ IH CSA (mm²)=(follow-up – post-intervention) IH CSA; and (5) Δ EEM CSA (mm²)=(follow-up – post-intervention) EEM CSA.

The analysis of the differences and changes of the Δ lumen CSA and the Δ IH CSA between control patients and patients who received radiation therapy has been previously reported in detail [11].

2.5. Reproducibility of IVUS measurements

Because stent filaments can interfere with the visualization of the EEM in stented segments, the reproducibility of measurements of the EEM was tested in a blind comparison performed by two independent operators in five in-stent restenosis lesions. The intraobserver and interobserver

correlation coefficients for EEM were 0.935 and 0.921, respectively.

2.6. Statistical analysis

Categorical data are presented as frequencies. Continuous data are presented as mean ± 1 S.D. Comparison between the patients who received radiation therapy and control patients was performed with unpaired or paired *t*-test. Linear regression analysis was performed to assess the relationship between the Δ EEM CSA and the Δ IH CSA and to evaluate the reproducibility of the IVUS measurements. We considered a *P*-value < 0.05 statistically significant.

3. Results

IVUS data are shown in Table 1. There were no statistically significant differences in the post-intervention IVUS variables between the control patients and patients who received radiation therapy.

In patients who received radiation therapy, the EEM CSA significantly increased from 16.4 ± 3.3 mm² post-intervention to 17.1 ± 3.3 mm² at follow-up (*P*=0.001). In control patients, the EEM CSA also significantly increased from 16.8 ± 4.0 mm² post-intervention to 17.4 ± 4.1 mm² at follow-up (*P*=0.008).

There were no statistically significant differences of the Δ EEM CSA between the two groups. The Δ EEM CSA was 0.7 ± 0.4 mm² in the radiation therapy group and 0.6 ± 0.4 mm² in the control group (*P*=0.389). At the follow-up lesion site, the Δ IH CSA correlated with the Δ EEM CSA in control patients (*r*=0.826, *P*=0.022), but not in radiation therapy patients (*r*=0.016, *P*=0.919) (Fig. 1).

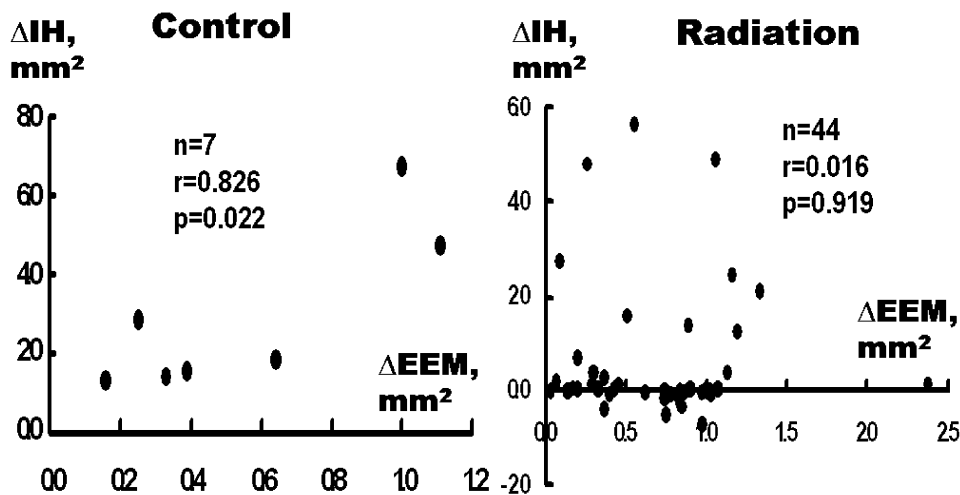


Fig. 1. The Δ intimal hyperplasia (IH) cross-sectional area (CSA) correlated with Δ external elastic membrane (EEM) CSA in control patients (*r*=0.826, *P*=0.022), but not in radiation therapy patients (*r*=0.016, *P*=0.919).

4. Discussion

4.1. De novo lesions after stenting

Several studies showed that the change within the stent was relatively homogeneous, namely, almost exclusively tissue growth [2,3]. However, the changes in the surrounding media and adventitia were complex. The short-term effects included thinning of the media and a possible rupture of the internal elastic membrane; the long-term effects included inflammatory infiltrate surrounding the stent wires, replacement of the media by myofibroblastic proliferation, and increases in collagen and mucopolysaccharide content of the media [14]. Serial IVUS study has shown that the vascular overstretch caused by stenting promoted IH in proportion to the degree of the sectional vascular stretch [15]. These results suggested that stretch or injury to the adventitia rather than to the intimal side played a significant role in neointimal proliferation in the stented lesions. These findings in stented lesions are consistent with those in nonstented lesions noted in an animal study, i.e. adventitial myofibroblasts contribute to the restenotic process by proliferating, synthesizing growth factors, and possibly migrating into the neointima after overstretch injury to the coronary arteries [16]. Additionally, tissue proliferation surrounding the stent occurs in proportion to neointimal proliferation. A previous IVUS study showed that there was a direct correlation between the increase in plaque mass inside and outside the stent [1]. This would suggest that positive remodeling surrounding the stents presumably occurs in response to extra-stent tissue proliferation [1]. However, a recent other IVUS study reported that there was a distinct trade-off between positive remodeling and in-stent hyperplasia [17]. In segments where the degree of extra-stent remodeling was less, neointimal proliferation within stent was greater [17]. Kay et al. reported that positive vascular remodeling was seen after catheter-based radiation followed by conventional stent deployment, but not after radioactive stent implantation in de novo lesions [18].

4.2. In-stent restenotic lesions

At the present time, no published data are available to evaluate EEM CSA changes and the relationships between Δ IH CSA and Δ EEM CSA in in-stent restenosis lesions. The current study showed that increased EEM CSA (positive remodeling) occurred in the in-stent restenosis lesions of patients who received radiation therapy as well as in those of control patients. The different treatment modalities did not influence the degree of positive remodeling between the two groups.

The increase in EEM CSA in the in-stent restenosis lesion of patients who received radiation therapy might be explained as follows: firstly, radiation therapy might be associated with positive vascular remodeling. However, there were no significant differences of Δ EEM CSA in

in-stent restenosis lesions between the radiation therapy and control groups in the current study. Therefore, these findings suggest that the effects of radiation therapy on positive vascular remodeling might be smaller in in-stent restenosis lesions compared with non-stented lesions. The radiation dosage in the current study was 15 Gy at 1.0 mm deep into the vessel wall. Compared with γ -radiation, the penetration depth of β -radiation is low; therefore, the rapid fall of the radiation dose of β -radiation energy within 2–5 mm might be associated with an inhomogeneous radiation dose delivery [19]. Furthermore, a shielding effect of stent struts has been reported with an up to 15% attenuation of radiation doses by the stent struts [20]. Therefore, if the depth of the plaque mass outside the stent is more than 1 mm in an in-stent restenosis lesion, it is somewhat difficult to deliver homogeneous and effective radiation energy to the adventitia. Secondly, the increase in EEM CSA in an in-stent restenosis lesion might be a non-specific response to injury. A previous IVUS study has demonstrated that positive remodeling surrounding the stents presumably occurs in response to extra-stent tissue proliferation in de novo lesions after stenting [1]. These earlier findings in de novo lesions after stenting might be applied to in-stent restenosis lesions.

In our current study, a direct relationship existed between the Δ IH area and Δ EEM area in the control group. However, compared with the control group, β -radiation therapy resulted in significant inhibition of IH. Therefore, we saw no such relationship between the Δ IH area and Δ EEM area in irradiated patients.

Our study has several limitations. Firstly, this was not a randomized placebo-controlled study. Secondly, the number of patients (especially in the control group) was small. Thirdly, this study was performed with β -radiation therapy with a $^{188}\text{Re-MAG}_3$ -filled balloon. Thus, the results of the present study cannot be compared to those of other studies that used different kinds of radiation sources, delivery methods, and interventional devices. Fourthly, we did not evaluate the influence of rotational atherectomy on extra-stent vascular remodeling in this study. Fifthly, we did not perform blind IVUS measurements between the two groups.

In conclusion, positive remodeling (increased EEM area) occurred equally in both the control and irradiated patients with in-stent restenosis. The extent of remodeling was directly in proportion to IH in the control group, but no such relationship existed in the irradiated group.

Acknowledgements

This work was partly supported by the Cardiovascular Research Foundation, Seoul, South Korea.

References

- [1] Hoffmann R, Mintz GS, Popma JJ, et al. Chronic arterial responses to stent implantation: a serial intravascular ultrasound analysis of Pal-

- maz–Schatz stents in native arteries. *J Am Coll Cardiol* 1996;28:1134–9.
- [2] Hoffmann R, Mintz GS, Dussaillant GR, et al. Patterns and mechanism on in-stent restenosis: a serial intravascular ultrasound study. *Circulation* 1996;94:1247–54.
- [3] Mudra H, Regar E, Klauss V, et al. Serial follow-up after optimized ultrasound-guided deployment of Palmaz–Schatz stents. In-stent intimal hyperplasia without significant reference segment response. *Circulation* 1997;95:363–70.
- [4] Mehran R, Dangas G, Abizaid AS, et al. Angiographic patterns of in-stent restenosis: classification and implications for long-term outcome. *Circulation* 1999;100:1872–8.
- [5] Sharma SK, Duvvuri S, Dangas G, et al. Rotational atherectomy for in-stent restenosis: acute and long-term results of the first 100 cases. *J Am Coll Cardiol* 1998;32:1358–65.
- [6] Lee SG, Lee CW, Cheong SS, et al. Immediate and long-term outcomes of rotational atherectomy versus balloon angioplasty alone for treatment of diffuse in-stent restenosis. *Am J Cardiol* 1998;82:140–3.
- [7] Waksman R, White LR, Chan RC, et al. Intracoronary γ -radiation therapy after angioplasty inhibits recurrence in patients with in-stent restenosis. *Circulation* 2000;101:2165–71.
- [8] Waksman R, Bhargava B, White LR, et al. Intracoronary β -radiation therapy inhibits recurrence of in-stent restenosis. *Circulation* 2000;101:1895–8.
- [9] Mintz GS, Weissman NJ, Fitzgerald PJ. Intravascular ultrasound assessment of the mechanisms and results of brachytherapy. *Circulation* 2001;104:1320–5.
- [10] Sabate M, Serruys PW, van der Giessen WJ, et al. Geometric vascular remodeling after balloon angioplasty and β -radiation therapy: a three-dimensional intravascular ultrasound study. *Circulation* 1999;100:1182–8.
- [11] Hong MK, Park SW, Moon DH, et al. Intravascular ultrasound analysis of beta radiation therapy for diffuse in-stent restenosis to inhibit intimal hyperplasia. *Cathet Cardiovasc Interv* 2001;54:169–73.
- [12] Park SW, Hong MK, Moon DH, et al. Treatment of diffuse in-stent restenosis with rotational atherectomy followed by radiation therapy with a rhenium-188-mercaptoacetyltriglycine-filled balloon. *J Am Coll Cardiol* 2001;38:631–7.
- [13] Tobis JM, Mallery J, Mahon D, et al. Intravascular ultrasound imaging of human coronary arteries in vivo: analysis of tissue characteristics with comparison to in vivo histologic specimens. *Circulation* 1991;83:913–26.
- [14] Karas SP, Gravanis MB, Santoian EC, Robinson KA, Anderberg KA, King III SB. Coronary intimal proliferation after balloon injury and stenting in swine: an animal model of restenosis. *J Am Coll Cardiol* 1992;20:467–74.
- [15] Koyama J, Owa M, Sakurai S, et al. Relation between vascular morphologic changes during stent implantation and the magnitude of in-stent neointimal hyperplasia. *Am J Cardiol* 2000;86:753–8.
- [16] Scott NA, Cipolla GD, Ross CE, et al. Identification of a potential role of the adventitia in vascular lesion formation after balloon overstretch injury of porcine coronary arteries. *Circulation* 1996;93:2178–87.
- [17] Nakamura M, Yock PG, Bonneau HN, et al. Impact of peri-stent remodeling on restenosis: a volumetric intravascular ultrasound study. *Circulation* 2001;103:2130–2.
- [18] Kay IP, Sabate M, Costa MA, et al. Positive geometric vascular remodeling is seen after catheter-based radiation followed by conventional stent implantation but not after radioactive stent implantation. *Circulation* 2000;102:1434–9.
- [19] Höher M, Wöhrle J, Wohlfrom M, et al. Intracoronary β -irradiation with a liquid ^{188}Re -filled balloon: six-month results from a clinical safety and feasibility study. *Circulation* 2000;101:2355–60.
- [20] Amols HI, Trichter F, Weinberger J. Intracoronary radiation for prevention of restenosis: dose perturbations caused by stents. *Circulation* 1998;98:2024–9.